



# A correlative study of mixed fungal infection with special emphasis on mucormycosis in covid-19 patients: An early diagnosis improves the patient outcome

**Saba Shakil<sup>1</sup>, Suhailur Rehman<sup>1</sup>, Jowairiya Hassan<sup>1</sup>**

*1. Department of pathology, Jawaharlal Nehru Medical College, Faculty of medicine, AMU, Aligarh, Uttar Pradesh, India*

**Saba Shakil**, Junior Resident

**Suhailur Rehman**, Assistant Professor

**Jowairiya Hassan**, Senior Resident

## Abstract

**Background:** Mucormycosis is rare but fatal angioinvasive fungal infection which require prompt diagnosis and treatment. These are opportunistic organisms that affect people who are immunocompromised or on some steroids/chemotherapy drugs. **Methods:** The present study was conducted on 48 clinically suspected cases of rhino-orbital mucormycosis. Patients were between 30-70 years and presented with complaints of pain and swelling in the rhino-orbital region. The samples were received in normal saline and crush/imprint smears were prepared and stained with H & E, PAP and PAS stains for rapid cytological evaluation and also correlated with histopathology. **Results:** Total of 48 specimens from patients with suspected mucormycosis were received in the department of pathology, JNMCH, Aligarh over a period of six months. On cytology, out of 48 suspected cases, 21 cases (43.8%) were found to be positive for isolated mucormycosis. 2 cases of mixed infection were also reported, 1 case each of mucor with candida (2%) and mucor with aspergillous (2%). 3 cases (6.3%) were reported as suspicious for mucormycosis and 22 cases (45.8%) were diagnosed as negative. On histopathological correlation, 39 cases (81.3%) were positive for mucormycosis and 9 cases (18.7%) were negative. Among 48 cases, 43 cases (89.6%) had history of covid infection/RT-PCR positive for covid infection. Diabetes was most

common co-morbid condition, present in 39 cases (81.3%). **Conclusions:** Timely diagnosis and early detection by crush/imprint smear saves the time and early treatment on the same day of admission can be started for such a lethal and angioinvasive condition.

**Key Words:** Mucormycosis, Covid-19, Pandemic, Mixed infection, Cytology

## INTRODUCTION

Mucormycosis is a rare but serious infection caused by a group of moulds called as mucormycetes. These moulds live throughout the environment. It is an angio-invasive opportunistic infection, characterised by tissue infraction and necrosis which can be fatal if not detected early. Uncontrolled diabetes mellitus has been shown to be the most important risk factor.<sup>1</sup> The rhino-orbital-cerebral (ROCM) form of mucormycosis is commonly seen in diabetic population as opposed to pulmonary mucormycosis which is commonly seen in patients with hematological malignancy and transplant recipients.<sup>1-3</sup> Although it has a low incidence rate, varying from 0.005 to 1.7 per million population, but recently many cases have been encountered that reveals a rapid increase in its incidence during the coronavirus pandemic.<sup>4</sup> In the last few months there has been a significant, exponential rise of the rhino-orbital-cerebral mucormycosis in the patients who have recovered from COVID-19 or still undergoing treatment for COVID-19.

Though the exact incidence is still unknown, the Government of India has taken the cognizance of the issue and has made mucormycosis as a notifiable disease as per the Epidemic Diseases Act 1897 Govt. of India. In a recent review by A. K. Singh et al. of mucormycosis cases reported worldwide and in India the main reasons for Mucorales growth in COVID-19 patients is reported as conducive environment in form of hypoxia, diabetes mellitus, poor glycemic control, high ferritin and decreased phagocytic activity of white blood cells (WBC).<sup>5</sup>

Secondary fungal infections were described in critically-ill ventilated COVID-19 patients in the initial reports from Wuhan, and subsequent studies from Europe reported variable frequencies of 3% to 33% of COVID-19 associated pulmonary aspergillosis (CAPA), with reports of azole resistant strains.<sup>6-10</sup> Herein, we present our study of 48 clinically suspected cases of rhino-orbital mucormycosis reported over a period of six months.

## METHODS:

The present study was conducted on 48 clinically suspected case of rhino-orbital mucormycosis at Jawaharlal Nehru Medical College and Hospital, AMU, Aligarh, India, over a period of six months. Patients were between

30-70 years and presented with complaints of pain and swelling in the rhino-orbital region. The samples were received in normal saline and crush/imprint smears were made and stained with H & E, PAP and PAS stains for rapid cytological evaluation and also correlated with histopathology. Patient's history, co-morbidities and imaging findings were obtained, recorded and analysed.

## RESULTS:

A total of 48 specimens from patients with suspected mucormycosis were obtained. On cytology, out of 48 suspected cases, 21 cases (43.8%) were positive exclusively for mucormycosis with broad, aseptate hyphae and having right-angled branching (Fig 5). 2 cases of mixed infection were also reported, 1 case each of mucor with aspergillous (2.1%) showing thin, septate hyphae with acute-angled branching and mucor with candida (2.1%) showing candidal spores (Fig.6). 3 cases (6.3%) were reported as suspicious for mucormycosis and 22 cases (45.8%) were diagnosed as negative. On histopathological correlation, 39 cases (81.3%) were positive for mucormycosis and 9 cases (18.7%) were negative (Table 1). On histopathology, broad aseptate fungal hyphae with right-angled branching were seen (Fig 7). On PAS staining, magenta color PAS positive fungal hyphae were reported which confirms the diagnosis of mucormycosis (Fig. 8).

All the cases presented with various clinical features, in which majority of the patient presented with facial pain and swelling, seen in 27 cases (56.3%), followed by periorbital pain, swelling and blackening in 15 cases (31.3%) (Table 2). Rhino-orbital region seemed to be the most common involved site, seen in 33 cases (68.6%) followed by rhino-orbito-cerebral region, seen in 8 cases (16.7%) (Table 3).

Among 48 cases, 43 cases (89.6%) had history of covid infection/RT-PCR positive for covid infection. Diabetes was the most common co-morbid condition, present in 39 cases (81.3%) followed by steroid intake, seen in 27 cases (56.3%) (Table 4).

The computerized tomography (CT) image showed high density collection filling paranasal sinuses with mucoperiosteal thickening of sinuses, destruction of bone, thickening of extraocular muscles and evidence of intracranial extension (Fig.3).

On follow-up, among 48 patients, 33 patients (68.8%) discharged in satisfactory condition, and 5 (10.4%) patients died during treatment.

**Table 1: Distribution of total cases**

No. of cases	Cytopathology (%)	Histopathology(%)
<b>Mucor</b>	<b>21 (43.8)</b>	<b>36(75)</b>
Mucor + Candida	1(2.1)	1(2.1)
Mucor + Aspergillous	1(2.1)	1(2.1)
Suspicious	3(6.3)	1(2.1)
Negative	22(45.8)	9(18.7)
<b>TOTAL</b>	<b>48(100)</b>	<b>48(100)</b>

**Table 2: Distribution of cases according to presenting complaints**

Presenting complaints	No. of cases (%)
<b>Facial pain, Swelling &amp; Non Healing Ulcer (Oral/Palatal)</b>	<b>27(56.3)</b>
<b>Periorbital pain, Swelling &amp; Blackening</b>	<b>15(31.3)</b>
Nasal bleeding/obstruction/discharge	9(18.6)
Headache	8(16.7)
Loosening of tooth /Tooth ache	6(12.5)
Diminution of vision	5(10.4)

**Table 3: Site occurrence of infection**

Location	No. of cases	Percentage(%)
Sino-Nasal	4	8.3
<b>Rhino-Orbital</b>	<b>33</b>	<b>68.6</b>
<b>Rhino-orbito-cerebral</b>	<b>8</b>	<b>16.7</b>
Rhino-Palatal	3	6.3
Rhino-Maxillary	1	2.1
<b>TOTAL</b>	<b>48</b>	<b>100</b>



**Table 4: Association with Covid-19 infection and other Co-morbid condition (n=48)**

Co-morbid Condition	Covid-19 history/ RTPCR Positive (%)	Diabetes (%)	Hypertension (%)	Thyroid disorder (%)	Oxygen (%)	Steroid (%)
Yes	<b>43(89.6)</b>	<b>39(81.3)</b>	8(16.7)	2(4.2)	16(33.3)	<b>27(56.3)</b>
No	5(10.4)	9(18.7)	40(83.3)	46(95.8)	32(66.7)	18(37.5)
Not sure	0	0	0	0	0	3(6.2)

p value <0.05 for association with Covid-19 history/RT PCR, Diabetes and Steroids.

**Table 5: Condition of patients on follow up**

On follow-up	No. of patient	Percentage(%)
<b>Discharged</b>	<b>33</b>	<b>68.8</b>
Death	5	10.4
Absconded	4	8.3
Re-admitted	2	4.2
Under treatment	4	8.3
<b>TOTAL</b>	<b>48</b>	<b>100</b>

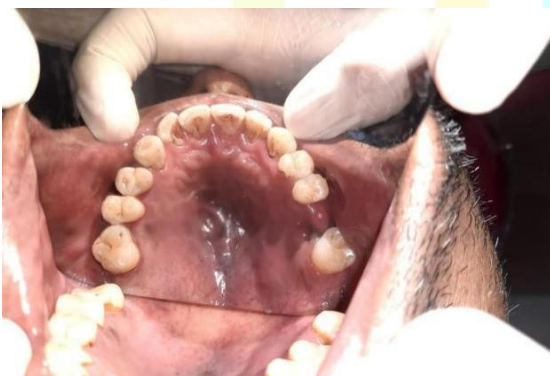

Fig 1. shows blackish discoloration of oral cavity

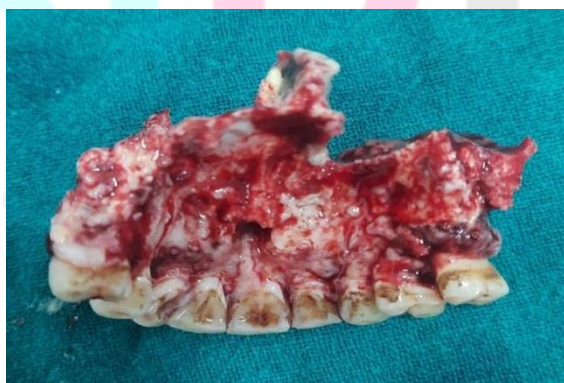

Fig 2. Post-op maxillectomy specimen showing destruction of bone and necrosis.

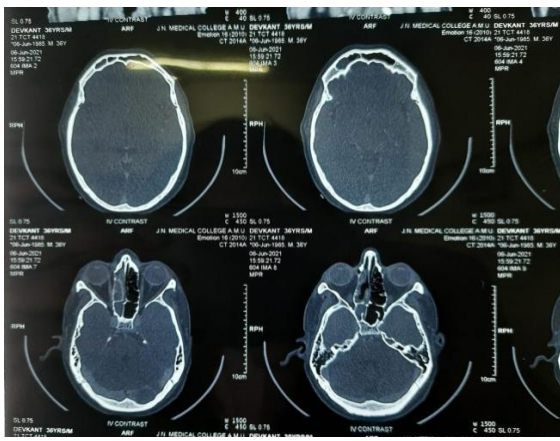


Fig 3: CECT: Mucoperiosteal thickening, involving bilateral maxillary, ethmoid and frontal sinuses.



Fig 4: showing blackening of eye ball along with haemorrhage and necrosis

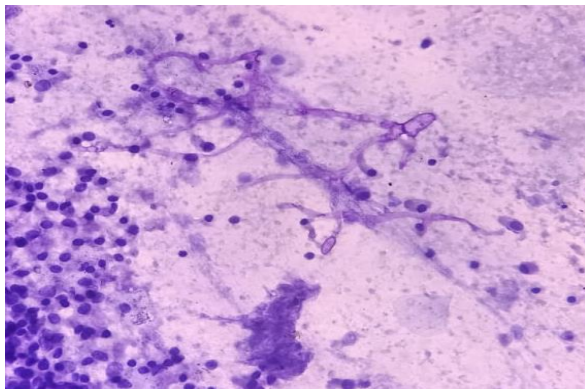


Fig 5:Crush smear/cytology shows broad,aseptate fungal hyphae with right-angled branching (H&E-40X).

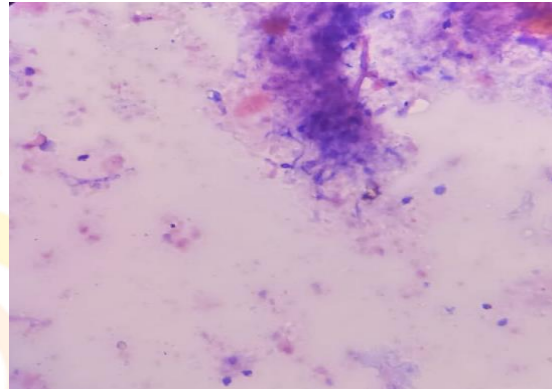


Fig 6: Smear shows mucor with broad aseptate hyphae along with candidal spores (H&E-40X).

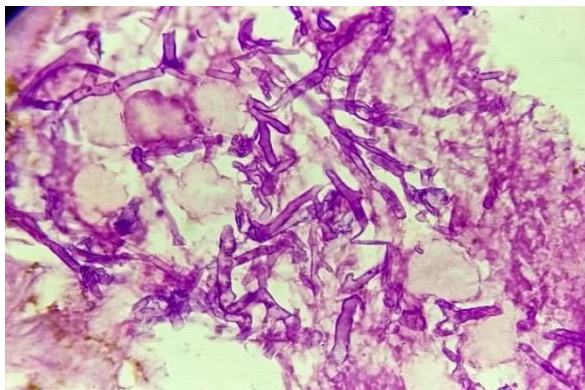


Fig 7: Section shows mucor with broad aseptate hyphae and right-angled branching (H & E-40 X).

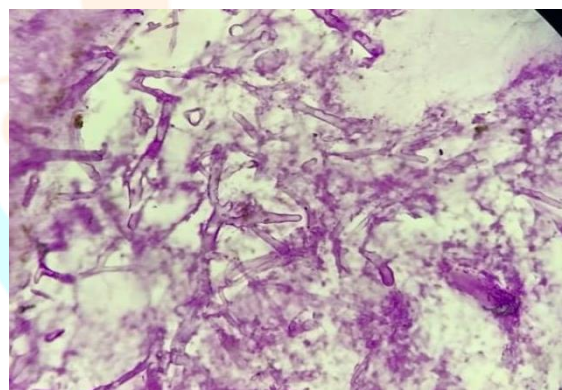


Fig 8: Section shows PAS positive fungal hyphae (PASx40X).

## DISCUSSION

With the second wave revealing further complexities of the pandemic, we have become more aware of the incompetency's of our current health system. Despite repeated attempts by central bodies to establish evidence-based guidelines, lack of affordable health care, inadequate and undersupplied government hospitals, availability

of over-the-counter medications, and a burden of undiagnosed diabetes have skyrocketed the cases of mucormycosis in the second wave of the pandemic.

A study done by Patel et al in June 2021 with 465 cases of mucormycosis without COVID-19 infection and analysed that most commonly involved site was rhino-orbital region (67.7%), followed by pulmonary type (13.3%) and cutaneous type (10.5%). Among Indian population, diabetes mellitus (73.5%) was found to be the most common risk factor followed by malignancy (9.0%) and organ transplantation.(11) In our study, rhino-orbital region was found to be the most common involved site (68.6%) followed by rhino-orbito-cerebral disease (16.5%). Gupta et al also documented rhino-orbito-cerebral disease in 20% of mucormycosis patients.(12) Our study also revealed that diabetes was the most common co-morbid condition seen in 81.3% cases followed by steroid therapy in 56.3% cases. John et al in their study also found that 93% of patients had diabetes mellitus and 80% of patients received steroids for COVID-19 infection.(13) In our study, 89.6% patient had positive history of COVID infection/RT-PCR positive for COVID infection. Similar study done by Song et al, Sen et al and Sharma et al who also documented increased risk of developing mucormycosis in patients affected by COVID-19.(14,15,16).

It cannot be stressed enough that the need for appropriate medication, in the right time and place, and for the right person is the need of the hour. With waves of the pandemic, it is of utmost importance to disseminate the right information amongst the public for COVID appropriate behaviour and at the same time try to strengthen our crumbling health systems to better prepare for what lies ahead.

## CONCLUSIONS

Timely diagnosis and early detection by crush/imprint smear saves the time and early treatment on the same day of admission can be started for such a lethal and angioinvasive condition. Additionally, possibility of mixed infection should also be taken into account, because treatment protocol is different and hence prognosis and outcome. It also provides an acceptable diagnostic accuracy when supported by histopathology.

## REFERENCES

- (1) Prakash H, Ghosh AK, Rudramurthy SM, Singh P, Xess I, Savio J, et al. A prospective multicenter study on mucormycosis in India: epidemiology, diagnosis, and treatment. *Med Mycol* 2019; June 1; 57(4):395-402.
- (2) Roden MM, Zaoutis TE, Buchanan WL, Knudsen TA, Sarkisova TA, Schaufele RL et al. Epidemiology and outcome of zygomycosis: a review of 929 reported cases. *Clin Infect Dis* 2005; 41:634-53.



- (3) Jeong W, Keighley C, Wolfe R, Lee WL, Slavin MA, Kong DCM et al. The epidemiology and clinical manifestations of mucormycosis: a systematic review and meta-analysis of case reports. *Clin Microbiol Infect* 2019;25:26-34.
- (4) Werthman-Ehrenreich A. Mucormycosis with orbital compartment syndrome in a patient with COVID-19. *Am J Emerg Med* 2021;42:264.e5–264.e8.
- (5) Singh AK, Singh R, Joshi SR, Misra A. Mucormycosis in COVID-19: A systematic review of cases reported worldwide and in India. *Diabetes Metab Syndr* 2021;15(4):102146-52.
- (6) Alanio A, Dellièrè S, Fodil S, Bretagne S, Mégarbane B. Prevalence of putative invasive pulmonary aspergillosis in critically ill patients with COVID-19. *Lancet Respir Med*. 2020;8(6):48-9.
- (7) White PL, Dhillon R, Cordey A, Hughes H, Faggian F, Soni S, et al. A national strategy to diagnose COVID-19 associated invasive fungal disease in the ICU. *Clin Infect Dis* 2021;73(7):1634-44.
- (8) Bartoletti M, Pascale R, Cricca M, Rinaldi M, Maccaro A, Bussini L, et al. Epidemiology of Invasive Pulmonary Aspergillosis Among Intubated Patients With COVID-19: A Prospective Study. *Clin Infect Dis*. 2021;73(11):3606-14.
- (9) Sarrazyn C, Dhaese S, Demey B, Vandecasteele S, Reynders M, Van Praet JT. Incidence, risk factors, timing, and outcome of influenza versus COVID-19-associated putative invasive aspergillosis. *Infect Control Hosp Epidemiol*. 2021;42(9):1149-50.
- (10) van Arkel ALE, Rijpstra TA, Belderbos HNA, van Wijngaarden P, Verweij PE, Bentvelsen RG. COVID-19-associated pulmonary aspergillosis. *Am J Respir Crit Care Med*. 2020;202(1):132-5.
- (11) Patel A, Kaur H, Xess I, Michael JS, Savio J, Rudramurthy S. A multicentre observational study on the epidemiology, risk factors, management and outcomes of mucormycosis in India. *Clin Microbiol Infect*. 2021;26(7):9-15.
- (12) Gupta S, Goyal R, Kaore NM. Rhino-orbital-cerebral mucormycosis: battle with the deadly enemy. *Indian J Otolaryngol Head Neck Surg*. 2020;72(1):104-11.
- (13) John TM, Jacob CN, Kontoyiannis DP. When uncontrolled diabetes mellitus and severe COVID-19 converge: the perfect storm for mucormycosis. *J Fungi (Basel)* 2021;7(4):298-303.



- (14) Song G, Liang G, Liu W. Fungal co-infections associated with global COVID-19 pandemic: a clinical and diagnostic perspective from China. *Mycopathologia*. 2020;185(4):599-606.
- (15) Sen M, Lahane S, Lahane TP, Parekh R, Honavar SG. Mucor in a viral land: a tale of two pathogens. *Indian J Ophthalmol*. 2021;69:244-52.
- (16) Sharma S, Grover M, Bhargava S, Samdani S, Kataria T. Post coronavirus disease mucormycosis: a deadly addition to the pandemic spectrum. *J Laryngol Otol*. 2021;135(5):442-7.

